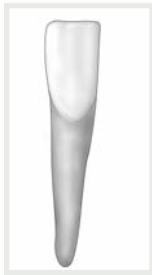

## • the permanent mandibular right central incisor

### Remember:

- The mandibular central incisor is the **least variable tooth** in the mouth. It is also the **smallest tooth** in the dentition. It is smaller than the mandibular lateral, which is not the case in the maxillary arch.
- The crown is very smooth and lacks anatomical features. The incisal outline is straight and perpendicular to the long axis. The mesial and distal incisal angles are almost  $90^\circ$ .
- The **3 smallest incisal embrasures** in the mouth in order are: in between the mandibular central incisors, in between the mandibular central and lateral incisors and in between the maxillary central incisors.
- The cingulum is **centered**.

### Mandibular Right Central Incisor



Labial



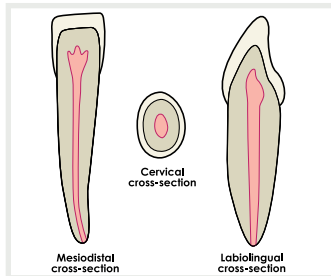
Incisal



Mesial



Distal



Mesiodistal cross-section

Labiolingual cross-section

### Mandibular Right Central Incisor Pulp Cavity