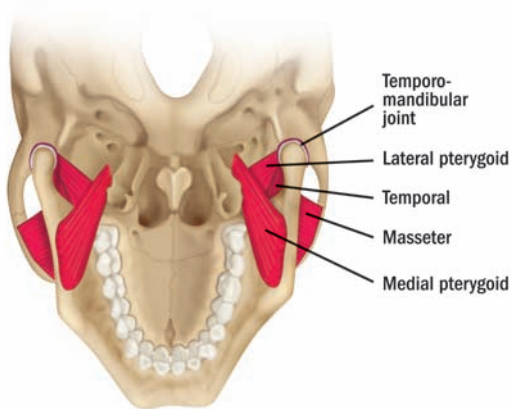
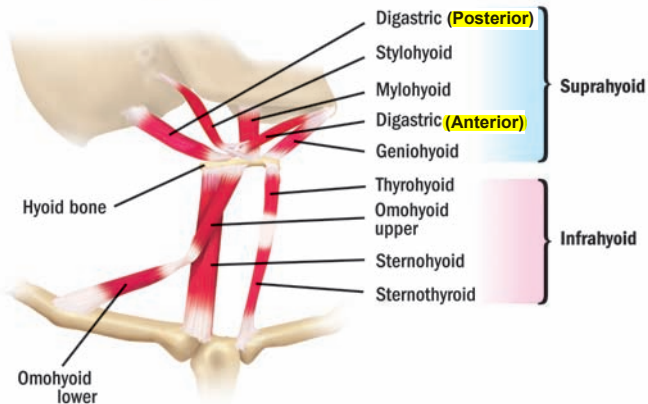


Posterior view of viscerocranium



Anterolateral view with head rotated slightly to the left



Muscles acting on the mandible / TMJ