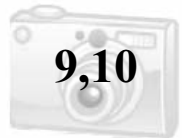

An 18-month-old boy diagnosed with Crouzon's syndrome needs to have surgery to treat the prematurely fused cranial bones. The joints in the flat bones of the fused cranium are classified as which of the following?

- Sutures
- Symphyses
- Synchondroses
- Syndesmoses



Sutures

Joints are places of union between two or more bones. Joints are classified on the basis of their structural features into fibrous, cartilaginous, and synovial types.

Fibrous joints (*synarthroses*): are barely movable or non-movable and are found in these forms:

- **Sutures** are connected by fibrous connective tissue and are found between the flat bones of the skull
- **Syndesmoses** are connected by fibrous connective tissue and occur as the inferior tibiofibular and tympanostapedial syndesmoses

Cartilaginous joints (*amphiarthroses*):

- **Synchondroses** (*primary cartilaginous joints*) are united by hyaline cartilage and permit no movement but growth in the length of the bone. These include epiphyseal cartilage plates and the first rib and sternum
- **Symphyses** (*secondary cartilaginous joints*) are joined by a plate of fibrocartilage and are slightly movable joints. These include the pubic symphysis and the intervertebral discs

Synovial joints (*diarthrodial joints*):

Permit a great degree of free movement. They are characterized by four features: **joint** (*synovial*) **cavity**, **articular cartilage**, **synovial membrane**, and **articular capsule**. These joints are classified according to axes of movement into:

- **Glding** (*plane*): include those joints found in the carpal bones of the wrist and the tarsal bones of the ankle
- **Hinge**: the elbow and knee joints are examples
- **Pivot**: joint such as is found between atlas (C1) and axis (C2) of the vertebral column
- **Ellipsoidal** (*condyloid*): found between the distal surfaces of the forearm bones (*radius and ulna*) and the adjacent carpal bones
- **Saddle**: found where the metacarpal of the thumb meets the trapezium of the carpus (*wrist*)
- **Ball-and-socket**: examples include the shoulder joint and the hip joint

A 26-year-old female has been previously diagnosed with McCune-Albright syndrome. There is bony fibrous dysplasia of the anterior cranial base leading to the encasement and narrowing of the optic canal. Although her vision is normal, there is concern that there will be compression of the optic nerve and which of the following other structure(s)?

- Ophthalmic nerve (*CN V-1*)
- Cranial nerves III, IV, and VI
- Ophthalmic artery
- Ophthalmic veins



Ophthalmic artery

The optic canal is located posteriorly in the lesser wing of the sphenoid. It communicates with the middle cranial fossa. It transmits the optic nerve and the ophthalmic artery.

Bony Opening	Location (<i>Bone</i>)	Contents
Cribriform plate with foramina	Ethmoid	Olfactory nerves
Hypoglossal canal	Occipital	Hypoglossal nerve
Carotid canal	Temporal	Internal carotid artery
Lacrimal canal	Maxilla and lacrimal	Nasolacrimal (<i>tear</i>) duct
Inferior orbital fissure	Sphenoid and maxilla	Infraorbital and zygomatic nerves from V ₂ , infraorbital artery, and ophthalmic vein
Superior orbital fissure	Sphenoid	Oculomotor, trochlear, and abducent nerves; lacrimal, frontal and nasociliary branches of ophthalmic nerve (V ₁); ophthalmic vein; sympathetic fibers from cavernous plexus
Optic canal and foramen	Sphenoid bone	Optic nerve and ophthalmic artery
Stylomastoid foramen	Temporal	Facial nerve

The external carotid artery terminates within the parotid gland, just behind the neck of the mandible, where the external carotid artery gives off two final branches, the _____ and the _____.

- Superficial temporal artery
- Superior thyroid artery
- Posterior auricular artery
- Occipital artery
- Maxillary artery
- Facial artery



Superficial temporal artery

Maxillary artery

The **external carotid artery** supplies structures within the neck, face, and scalp, and also supplies the maxilla and tongue. As with the internal carotid artery, the external carotid artery begins at the upper border of the thyroid cartilage (*i.e.*, *at the termination of the common carotid artery and the carotid sheath*). The external carotid artery terminates within the parotid gland, just behind the neck of the mandible, where the artery gives off two final branches, the **superficial temporal** and the **maxillary arteries**. **Note:** At its origin, where pulsations can be felt, the external carotid artery lies within the carotid triangle.

Branches of the external carotid:

- **Superior thyroid artery** - supplies thyroid gland, gives off a branch to the sternocleidomastoid muscle and superior laryngeal artery
- **Lingual artery** - supplies the tongue
- **Facial artery** - supplies the face, including lips and the submandibular gland
- **Ascending pharyngeal artery** - supplies the pharyngeal wall
- **Occipital artery** - supplies the pharynx and suboccipital triangle
- **Posterior auricular artery** - supplies back of the scalp
- **Maxillary artery** - terminal branch of external carotid, it gives off branches to the mandible, and the middle meningeal artery before passing through the pterygomaxillary fissure to enter the pterygopalatine fossa to supply the maxilla
- **Superficial temporal artery** - terminal branch of external carotid, supplies skin over frontal and temporal regions of scalp

Important: The external carotid artery and its branches supply the muscles of the neck and face, thyroid gland, salivary glands, scalp, tongue, jaws, and teeth.

Which intestinal enzyme breaks down the O-glycosidic bond between glucose and fructose?

- Maltase
- Lactase
- Sucrase

Sucrase

A disaccharide is a carbohydrate whose molecules contain two sugar units.

Examples include:

- **Maltose** (“*beer sugar*”) - consists of two glucose molecules joined together by a reaction (*condensation reaction*) in which a molecule of water is removed. This reaction produces a bond between the two glucose molecules called a **glycosidic bond**. The intestinal enzyme **maltase** promotes the conversion of **maltose into glucose**.
- **Lactose** (“*milk sugar*”) - consists of glucose and galactose. The intestinal enzyme **lactase** promotes the conversion of lactose into **glucose and galactose**.
- **Sucrose** (“*table sugar*”) - consists of glucose and fructose. The intestinal enzyme **sucrase** (*invertase*) promotes the conversion of sucrose into **glucose and fructose**.

Remember: The final digestion of these substances (*disaccharides*) to **absorbable monosaccharides** is completed by enzymes of the small intestine (*maltase, sucrase, and lactase*). These monosaccharides can then be absorbed by enterocytes.

Monosaccharides can be linked by **glycosidic bonds** to create larger structures (*disaccharides, oligosaccharides, and polysaccharides*). These bonds form when the **hydroxyl group** on the anomeric carbon of a monosaccharide reacts with an –OH or –NH group of another compound (*typically an alcohol, purine, pyrimidine, or in this case another sugar*). Maltose, lactose, and sucrose consist of monosaccharides joined by an **O-glycosidic bond**.



1. If oxygen is involved, this bond is classified as **O-glycosidic**; if nitrogen is involved, this bond is classified as **N-glycosidic**.
2. **D-glucose** is a **monosaccharide**, the most important of the aldohexoses.

The most abundant glycosaminoglycan in the body is:

- Keratan sulfate
- Dermatan sulfate
- Chondroitin sulfate
- Heparin sulfate

Chondroitin sulfate

Chondroitin sulfate is a major constituent in various connective tissues, especially in the **ground substance** of blood vessels, bone, and cartilage. In cartilage chondroitin sulfate, provides structure by holding water and nutrients, and allowing other molecules to move through cartilage - an important property, as there is no blood supply to cartilage. Chondroitin may work by acting as a building block for proteoglycan molecules, and may also have anti-inflammatory properties.

Important: In our joints, chondroitin sulfate contributes to strength, flexibility, and shock absorption.

Remember: The **extracellular space** in animal tissues is filled with a **gel-like material**, the extracellular matrix, also called **ground substance**, which holds the cells of a tissue together and provides a porous pathway for the diffusion of nutrients and oxygen to individual cells. The ground substance is composed of an **interlocking meshwork** of heteropolysaccharides (*glycosaminoglycans*), most covalently linked to protein forming proteoglycans, and fibrous proteins.

Important: **Hyaluronidase** will promote **depolymerization** of the extracellular matrix (*ground substance*). **Hyaluronidase** is an enzyme that splits hyaluronic acid (*glycosaminoglycan*) and so lowers its viscosity and increases the permeability of connective tissue and the absorption of fluids.



1. Heparin contains the **largest proportion** of sulfate (*yes, even more than heparin sulfate*).
2. Hyaluronic acid contains the **least proportion** of sulfate.

Which of the following globin chains are not commonly found in humans?

- Alpha
- Beta
- Gamma
- Omega

A Molecule of Hemoglobin Is Composed of the Following:

1. Globin (*protein*) portion

- Consists of **four** polypeptide chains - two alpha chains and two beta chains.
- The normal adult globin portion of Hb consists of two alpha and two beta chains, and the normal fetal globin portion of Hb consists of two alpha and two gamma chains.

2. Four ring-shaped heme molecules (*non-protein groups*)

- Each heme is a nitrogen-containing organic pigment molecule that has a single atom of iron in the reduced state (Fe^{2+} or *ferrous iron*) in its center, which can combine with one molecule of oxygen. These heme groups are attached to the globin polypeptide chains.

Each iron atom can **bind reversibly** with one molecule of oxygen; therefore, a hemoglobin molecule can potentially associate with **four oxygen** molecules. When it is combined with oxygen, the compound is called **oxyhemoglobin**. When the hemoglobin molecule is not combined with oxygen, the compound is called **deoxyhemoglobin** (*reduced*



1. Hemoglobin combines reversibly with **carbon dioxide** at the **protein portion** of the hemoglobin molecule.
2. Carbon monoxide **decreases** the amount of oxygen that can be transported by hemoglobin by competing with oxygen for hemoglobin binding sites. Carbon monoxide has a **much higher affinity** (*240 x stronger*) for hemoglobin than does oxygen.
3. As **pH decreases**, so does the affinity of hemoglobin for oxygen.
4. **Methemoglobin** contains iron in the ferric state (Fe^{3+}) and cannot function as an oxygen carrier.
5. Hemoglobin is a **major H⁺ buffer** of the blood. Deoxygenated hemoglobin is less acidic than oxygenated hemoglobin and therefore ideally suited to buffer the H⁺ ions (*coming from tissue CO₂*).

A stray crown is found in your office. It is an anterior incisor and has a cingulum that is offset from center. What tooth is it most likely to be?

- Maxillary central incisor
- Maxillary lateral incisor
- Mandibular lateral incisor
- Mandibular central incisor

Mandibular lateral incisor

A **cingulum** is a large, rounded eminence on the lingual surface of all permanent and primary anterior teeth.

Anterior teeth that have a cingulum which is located in the **center** of the cervical third of the lingual surface:


- Maxillary lateral incisor
- Maxillary canine
- Mandibular central incisor

Anterior teeth that have a cingulum which is located **off center to the distal** in the cervical third of the lingual surface:

- Maxillary central incisor
- Mandibular lateral incisor
- Mandibular canine

Note: The **total number** of cingula in each dentition is **twelve** (*six maxillary anterior teeth and six mandibular anterior teeth*).

Mandibular Right Lateral Incisor



Incisal

Mandibular Right Central Incisor



Incisal

A clinical examination of your patient reveals two lower incisors centered on the midline. The patient gives a history of a car accident when he was young where he lost two of his lower front teeth. He says that his dentist used braces to fill in the gaps. Which of the following criteria would be most reliable to decide if the remaining teeth were lateral or central incisors?

- Difference in root length
- Difference in ratio of crown length to root length
- Degree of slope of the incisal edge when viewed facially
- Difference in rotation of the crown on the root

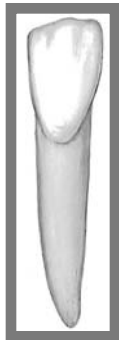Difference in rotation of the crown on the root

*** The mandibular **lateral incisor** crown tips slightly to the distal relative to the root (*facial view*).

Other ways to distinguish the mandibular lateral from the mandibular central:

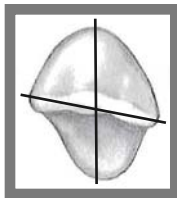
- The lateral is **larger overall** (*especially mesiodistally*)
- The lateral is **not as** bilaterally symmetrical as the central incisor
- The cingulum on the lateral is **slightly distal** to the center
- On the lateral incisor, the mesial marginal ridge is **longer** than the distal marginal ridge. On centrals, they are the same length
- Lateral incisors have the distal proximal contacts **more apical** than the mesial contacts. Centrals are at the same level
- Lateral incisors have the distoincisor angles **more rounded** than the mesioincisor angles. On centrals, the angles are nearly the same

Note: Both the mandibular **central** and **lateral** have a lingual cervical line that is positioned more apically than the facial cervical line.

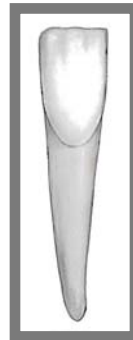


Labial

**Mandibular Right
Lateral Incisor**

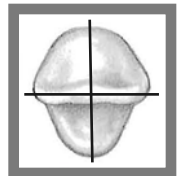


Incisal



Labial

**Mandibular Right
Central Incisor**



Incisal

Which of the following statements best describes the pulp canal of the mandibular lateral incisor?

- An elliptical shape, consistently wider in the mesiodistal direction
- An elliptical shape, consistently wider in the faciolingual direction
- An elliptical shape, wider in the mesiodistal direction in the pulp chamber, but wider in the faciolingual direction in the mid-root area
- An elliptical shape, wider in the faciolingual direction in the pulp chamber, but wider in the mesiodistal direction in the mid-root area

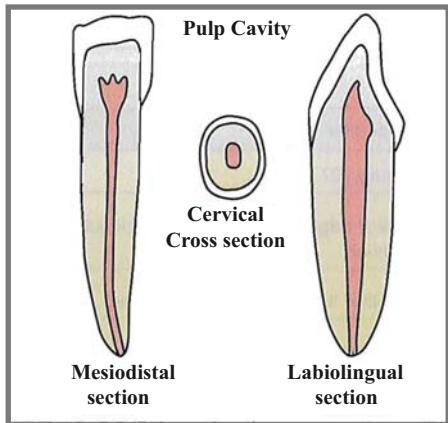
An elliptical shape, wider in the mesiodistal direction in the pulp chamber, but wider in the faciolingual direction in the mid-root area

Near the roof of the pulp chamber, the elliptical form of the pulp cavity is widest in the **mesiodistal** direction; however, near mid-root the elliptical form is widest in the **faciolingual** direction. A small percentage have two canals.

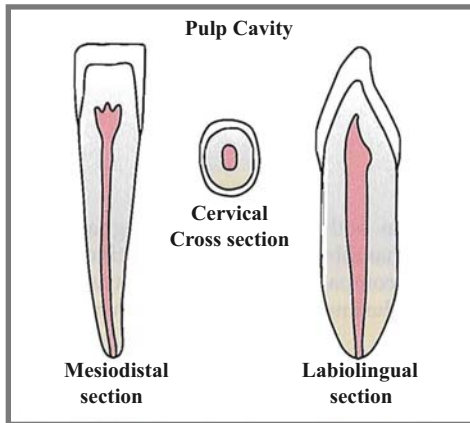
Notes

1. Compared to the mandibular central incisor, the mandibular lateral incisor's root is **larger in all dimensions**.
2. The crown of the mandibular **lateral incisor** tips slightly to the **distal** relative to the root; thus, the **cingulum** is slightly off-center to the distal, like that of the maxillary central incisor and mandibular canine, **but unlike** that of the mandibular central incisor.
3. The incisal edge of the **mandibular lateral** is slightly curved or rotated on the distal. For this reason it is possible to see a small portion of this distal-incisal edge when viewing this tooth from the mesial aspect.

Mandibular Right Lateral Incisor



Mandibular Right Central Incisor



Which of the following is the predominant type of bacteria on the skin?

- Lactobacilli
- Lactic acid bacteria
- Neisseria
- Staphylococci

Staphylococci

Predominant bacteria at various anatomical locations in adults

Anatomical Location	Predominant bacteria
Skin	Staphylococci and corynebacteria
Conjunctiva	Sparse: gram-positive cocci and gram negative rods
Oral cavity:	
Teeth	Streptococci, lactobacilli
Mucous membranes	Streptococci and lactic acid bacteria
Upper respiratory tract	
Nares (<i>nasal membranes</i>)	Staphylococci and corynebacteria
Pharynx (<i>throat</i>)	Streptococci, neisseria, Gram-negative rods and cocci
Lower respiratory tract	None
Gastrointestinal tract	
Stomach	<i>Helicobacter pylori</i> (up to 50%)
Small intestine	Lactics, enterics, enterococci, bifidobacteria
Colon	Bacteroides, lactics, enterics, enterococci, clostridia
Urogenital tract	
Anterior urethra	Sparse: Staphylococci, corynebacteria, enterics
Vagina	Lactic acid bacteria during child-bearing years; otherwise mixed

In addition to peptidoglycan, the acid-fast cell wall of Mycobacterium contains a large amount of glycolipids, especially _____ that make up approximately 60% of the acid-fast cell wall.

- Beta-lactamases
- Lipopolysaccharides
- Teichoic acids
- Mycolic acids

Mycolic acids

These mycolic acids are localized in the inner leaflet of the mycobacterial cell wall either covalently bound or loosely associated with arabino-galactan polymers.

Functions of the Acid-Fast Cell Wall Components:

1. The **peptidoglycan** prevents osmotic lysis.
2. The **mycolic acids** and other glycolipids also **impede the entry** of chemicals causing the organisms to grow slowly and be more resistant to chemical agents and lysosomal components of phagocytes than most bacteria.
3. The **surface proteins** in the acid-fast cell wall, depending on the strain and species, carry out a variety of activities, including:
 - Functioning as enzymes
 - Serving as adhesins. Adhesins enable the bacterium to adhere intimately to host cells and other surfaces in order to colonize and resist flushing.
4. The **periplasm** contains enzymes for nutrient breakdown as well as periplasmic binding proteins to facilitate the transfer of nutrients across the cytoplasmic membrane.



Notes

1. **Isoniazid** inhibits mycolic acid biosynthesis and is an efficient antimycobacterial agent.
2. A **tubercle** or **Ghon focus** is a small, rounded nodule produced by infection with *M. tuberculosis*. It is the **primary lung lesion** of pulmonary TB.

DNA in the bacterial cell is generally confined to the:

- Ribosomes
- Inclusions
- Capsule
- Nucleoid

Nucleoid

Characteristics of Typical Bacterial Cell Structures	
Structure	Function
Nucleoid	DNA is generally confined to this central region
Ribosomes	Site of translation (<i>protein synthesis</i>)
Inclusions (<i>storage granules</i>)	Storage of reserves of nutrients
Capsule	Layer of polysaccharides (<i>occasionally proteins</i>); attachment to surfaces; protection against phagocytosis
Cell wall <ul style="list-style-type: none">• Gram-positive bacteria• Gram-negative bacteria	Prevents osmotic lysis of cell protoplast and confers rigidity and shape to cells Peptidoglycan prevents osmotic lysis and confers rigidity and shape; outer membrane is permeability barrier; associated LPS (<i>endotoxin</i>) and proteins have various functions.
Plasma membrane	Permeability barrier; transport of solutes; energy generation; location of numerous enzyme systems
Chromosome	Genetic material of cell
Plasmid	Extrachromosomal genetic material
Flagella	Motility (<i>swimming movement</i>)
Pili <ul style="list-style-type: none">• Sex pilus• Common pili or fimbriae	Mediates DNA transfer during conjugation Attachment to surfaces; protection against phagocytosis

The **cell envelope** is a descriptive term for the several layers of material that envelope or enclose the protoplasm of the cell. The cell protoplasm (**cytoplasm**) is surrounded by the plasma membrane, a **cell wall** and a **capsule**. The cell wall itself is a layered structure in gram-negative bacteria. All cells have a **plasma membrane**, which is the essential and definitive characteristic of a “cell.” Almost all procaryotes have a cell wall to prevent damage to the underlying protoplast. Outside the cell wall, foremost as a surface structure, may be a polysaccharide **capsule or glycocalyx**.