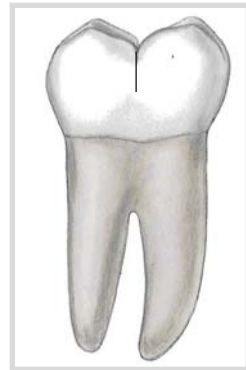


The photo below is:

- The buccal view of a permanent mandibular right second molar
- The lingual view of a permanent mandibular right second molar
- The buccal view of a permanent mandibular right first molar
- The lingual view of a permanent mandibular right first molar

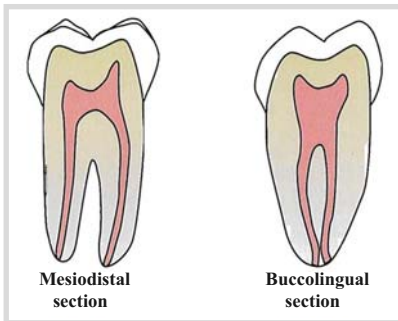
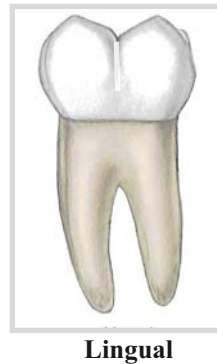
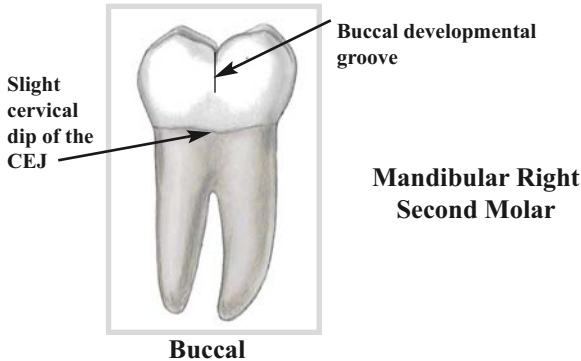


Reproduced with permission from Bath-Balogh M, Fehrenbach MJ; Illustrated dental embryology, histology, and anatomy, ed 2, St. Louis, 2006, Saunders.

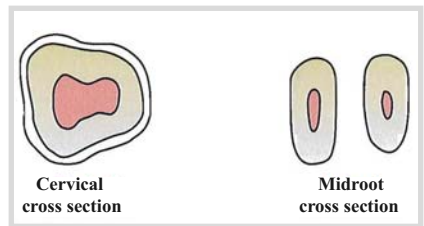
## The buccal view of a permanent mandibular right second molar

\*\*\* Keys to distinguish between the buccal aspect and lingual aspect:

- On the **buccal**, there is a slight cervical dip of the CEJ; there is **no dip** at all on the lingual
- The **buccal developmental groove** extends almost halfway down the buccal surface and ends in a pit; on the lingual, the groove **only extends slightly** onto the lingual surface



**Mandibular Right Second Molar Pulp Cavity**



Reproduced with permission from Bath-Balogh M, Fehrenbach MJ; Illustrated dental embryology, histology, and anatomy, ed 2, St. Louis, 2006, Saunders.